

# Clinical guidelines for the use of Protaper Next instruments: part two

Peet J van der Vyver and Michael J Scianamblo illustrate the use of Protaper Next instruments in difficult and challenging endodontic cases

Recently, the Protaper Next system (Dentsply/Maillefer) was launched into the dental market. In part one of this series, published in December's issue of *Endodontic Practice*, the authors outlined the clinical guidelines for the use of the Protaper Next instruments.

There are five instruments in the system but most canals can be prepared by using only the first two instruments. The first instrument in the system is the Protaper Next X1, with a tip size of 0.17mm and a 4% taper. This instrument is used after creation of a reproducible glide path by means of hand instruments or rotary Pathfiles (Dentsply/Maillefer). The Protaper Next X1 is always followed by the second instrument: the Protaper Next X2 (0.25mm tip and 6% taper). The Protaper Next X2 can be regarded as the first finishing file in the system as it leaves the prepared root canal with adequate shape and taper for optimal irrigation and root canal obturation. The PTN X1 and X2 have an increasing and decreasing percentage tapered design over the active portion of the instruments. The last three finishing instruments are the Protaper Next X3 (0.30mm tip with 7% taper), Protaper Next X4 (0.40 mm tip with 6% taper) and the Protaper Next X5 (0.5mm tip with 6% taper). These instruments have a decreasing percentage taper from the tip to the shank. The Protaper Next X3, X4 and X5 can be used to either create more taper in a root canal or to prepare larger root canal systems.

The advantages of the Protaper Next system include:

- The instruments are manufactured from M-Wire that contributes towards more flexible instruments, increased safety and protection against instrument fracture (Gutmann, Gao, 2012) allowing the clinician to treat more complex root canal systems with a high level of success
- The instruments have a bilateral symmetrical rectangular cross section with an offset from the central axis of rotation (except in the last 3mm of the instrument, D0-D3) creating an asymmetric rotary motion. The exception is the Protaper X1, which has a square cross section in the last 3mm to give the instruments a bit more core strength in the narrow apical part. The asymmetric rotary motion allows the instrument to experience a rotational phenomenon known as precession or swagger (Scianamblo, 2011). According to Van der Vyver and Scianamblo (2013), the benefits of this design characteristic include:

1. It further reduces (in addition to the progressive tapered design) the engagement between the instrument and the dentine walls because only two cutting points make contact with the canal wall at any time. This will contribute to a reduction in taper lock, screw-in effect and stress on the file
2. It ensures debris removal in a coronal direction because the off-centre cross-section allows for more space around the



## CPD Aims and objectives

This clinical article aims to provide clinical guidelines for the use of Protaper instruments in complex and challenging endodontic cases.

## Expected outcomes

Correctly answering the questions on page xx, worth one hour of verifiable CPD, will demonstrate you understand the principles described in this article.

flutes of the instrument. This will lead to improved cutting efficiency, as the blades will stay in contact with the surrounding dentine walls. Root canal preparation is done in a very fast and effortless manner

3. The swaggering (asymmetric) rotary motion of the instrument initiates activation of the irrigation solution during canal preparation, improving debris removal
4. Reduces the risk of instrument fracture because there is less stress on the file and more efficient debris removal
5. Every instrument is capable of cutting a larger envelope of motion (larger canal preparation size) compared to a similarly-sized instrument with a symmetrical mass and axis of rotation. This allows the clinician to use fewer instruments to prepare a root canal to the adequate shape and taper to allow for optimal irrigation and obturation
6. There is a smooth transition between the different sizes of instruments because the design ensures that the instrument sequence itself expands exponentially.

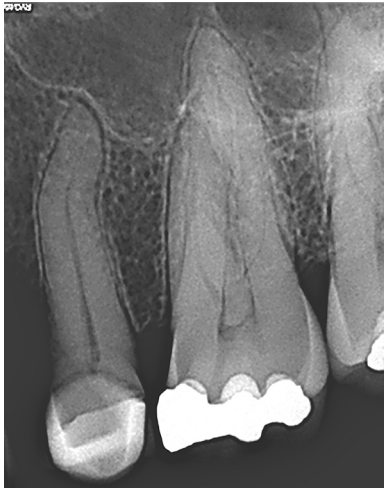The aim of this article is to illustrate the use of Protaper Next instruments in complex and challenging endodontic cases. The preparation technique for minimally invasive root canal preparation with Protaper Next instruments will also be discussed.

## 'S'-shaped root canals

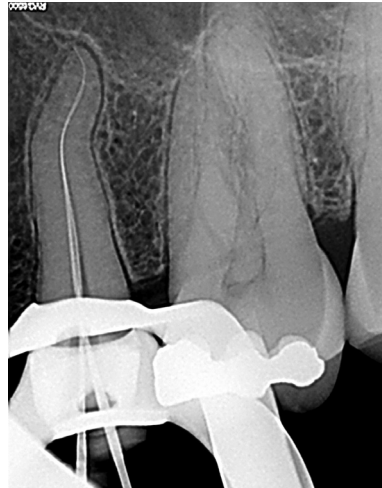A major challenge in endodontics is the treatment of 'S'-shaped or bayonet-shaped root canals. This type of root canal configuration can be present in root canal systems of maxillary laterals, canines and premolars, as well as

Peet J van der Vyver is extraordinary professor at the Department of Odontology, School of Dentistry, University of Pretoria and Private Practice, Sandton, South Africa (see [www.studio4endo.com](http://www.studio4endo.com) for more).

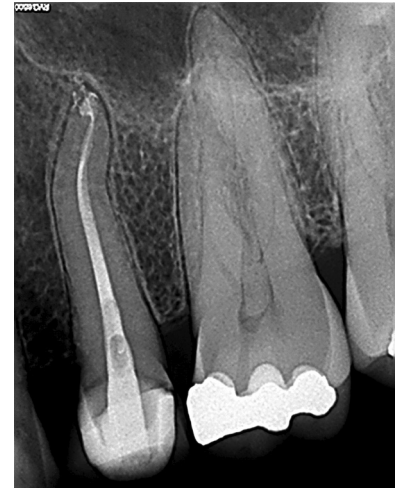Michael J Scianamblo DDS is an endodontist and the developer of Critical Path Technology. He is a postgraduate and fellow of the Harvard School of Dental Medicine and has served as a faculty member of the University of the Pacific and the University of California, Schools of Dentistry in San Francisco.



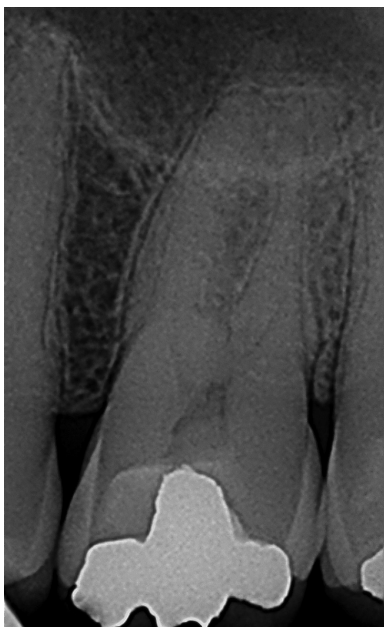
**Figure 1a:** Preoperative radiograph of a maxillary right second premolar



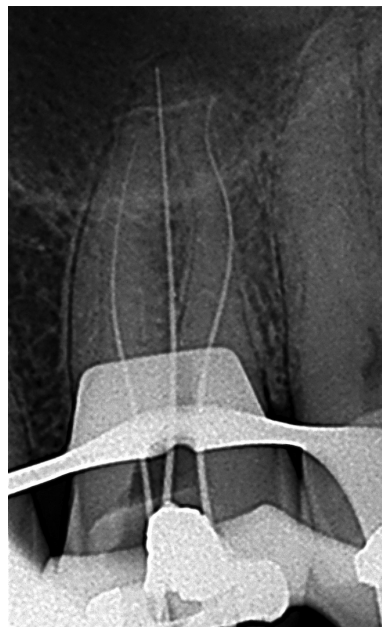
**Figure 1b:** Length determination radiograph. Note the 'S'-shaped canal configuration



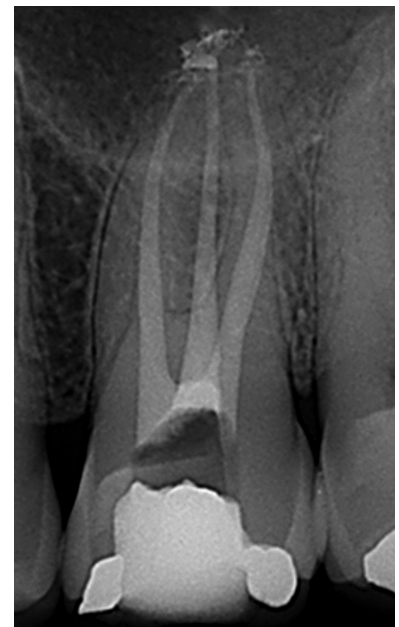**Figure 1c:** Postoperative radiograph after canal obturation with Guttacore obturators (Dentsply/Maillefer)



**Figure 2a:** Preoperative radiograph of a maxillary right first molar



**Figure 2b:** Length determination radiograph. Note the 'S'-shaped canal configuration in the distobuccal root canal



**Figure 2c:** Postoperative radiograph after glide path preparation with Pathfiles and canal preparation with Protaper Next X1 and X2. Obturation was done with Guttacore obturators. Note maintenance of 'S'-shaped curvature in the obturated distobuccal root canal system

mandibular molars (Rueben et al, 2008). The authors would recommend using Pathfile no. 3 (ISO tip 0.19mm) (after Pathfiles no. 1 and 2) in these challenging root canal systems as the final glide path preparation file. This will increase the glide path size before introducing the Protaper Next X1, resulting in less engagement as the file travels down the canal curvatures.

#### Case report one

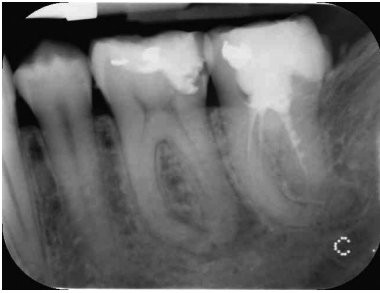The patient, a 41-year-old female presented with irreversible pulpitis on her maxillary right second premolar (Figure 1a). The length determination radiograph revealed an 'S'-shaped canal configuration (Figure 1b). The canal was negotiated and glide path enlarged using Pathfiles no. 1, 2 and 3. Canal

preparation was done with Protaper Next X1 and X2.

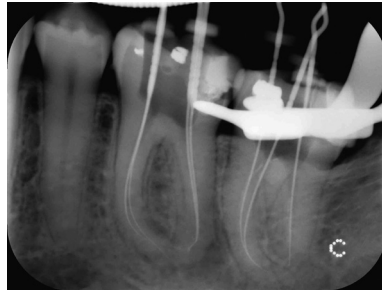In this case, emphasis was placed on using a backstroke, outwards brushing motion with the Protaper Next instruments to remove restrictive dentine in the canal, allowing the instruments to progress apically. The canal was obturated (Figure 1c) with a size 20 Guttacore obturator to working length followed by another X2 Guttacore obturator to ensure adequate obturation of the oval coronal part of the root canal system.

#### Case report two

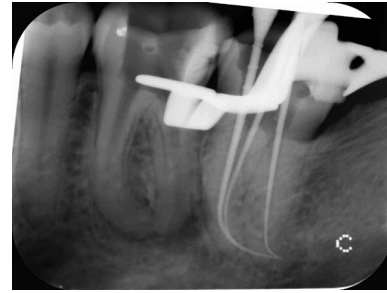A 45-year-old male patient presented with severe pain on his maxillary right first molar. A preoperative periapical radiograph revealed placement of a deep amalgam restoration (Figure 2a).



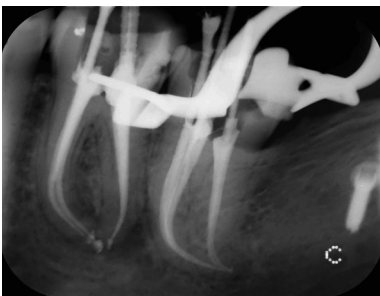
**Figure 3a:** Non-vital mandibular left first molar and inadequately root canal treated mandibular right second molar



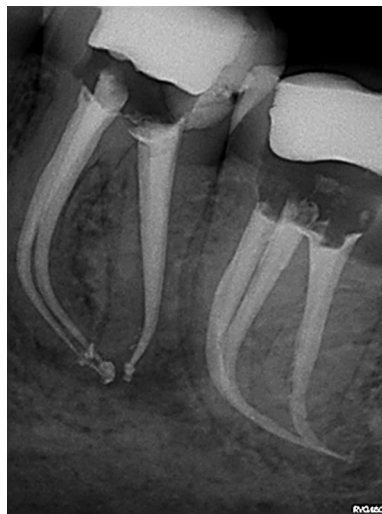**Figure 3b:** Initial length determination radiograph. Note that the files were short in all the root canals in the mandibular second molar



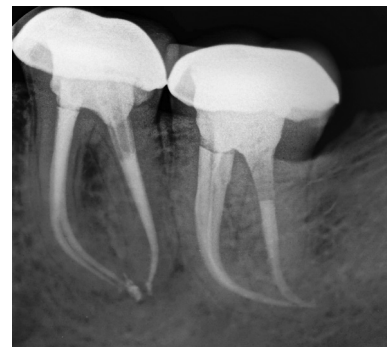**Figure 3c:** Periapical radiograph demonstrating the fit of the plastic inserts of Protaper obturators to the corrected working length (mandibular second molar) after canal negotiation with C+ and K-files and preparation with Protaper Next



**Figure 3d:** Final result after the canals were obturated with Protaper obturators



**Figure 3e:** Periapical radiograph (30 degrees mesial angulated) demonstrating respect of the original canal anatomy after canal preparation with Protaper Next instruments



**Figure 3f:** Six-month follow-up periapical radiograph illustrating periapical healing

The length determination radiograph revealed an 'S'-shaped canal configuration in the distobuccal root canal (Figure 2b). The root canals were negotiated to working length and the glide paths enlarged using Pathfiles no. 1 and no. 2. Pathfile no. 3 was used in the distobuccal root canal. Canal preparation was done with Protaper Next X1 and X2 in all three root canals.

After gauging with a size 25 nickel titanium hand instrument it was decided to enlarge the palatal root canal to a Protaper Next X3. All three root canals were obturated with matching Protaper Next gutta percha cones using the Calamus Dual Obturation Unit (Figure 2c). Note the maintenance of the 'S'-shaped curvature in obturated distobuccal root canal system.

### Challenging curvatures in the apical third of root canals

Apical root canal curvatures must always be respected and never straightened. According to Catellucci (2005), straightening these curves would mean displacing the apical foramen from its original position, which can lead to treatment failure. Other problems that can be encountered when treating curved canals include ledge formation, perforation, zip formation and file separation (Ingle, 2005).

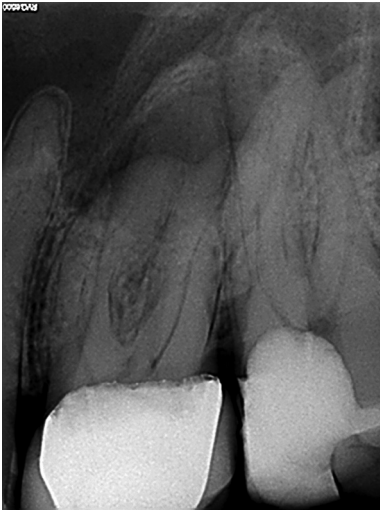It is very important to identify canal curvatures during initial canal negotiation in order to avoid the above mentioned preparation errors. The greater the angle of curvature and the smaller the radius of curvature, the more complex the management and treatment will be (Pruett, Clement, Carnes, 1997).

Again, the authors would recommend using all three Pathfiles in these challenging root canal systems to enlarge the glide path prior to canal preparation. It is also important to note that the reduced apical tapers of the Protaper Next instruments (compared to Protaper Universal) are ideal for maintaining apical curvatures or 'S'-shaped root canals.

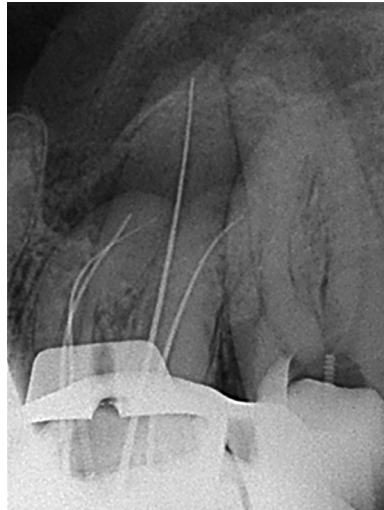### Case report

The patient, a 27-year-old male, presented with a non-vital mandibular left first molar and an inadequately root canal treated mandibular right second molar (Figure 3a). Access cavities were prepared and the previous gutta percha was removed from the canals of the second molar.

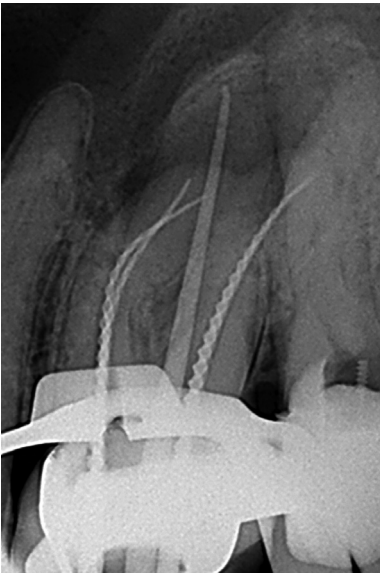
A length determination radiograph revealed sharp apical curvatures in the last few millimetres of the mesial and distal roots of the mandibular first molar. It was also noted that the working length was short in the canals of the second molar (Figure 3b). A combination of C+ and K-files were used to



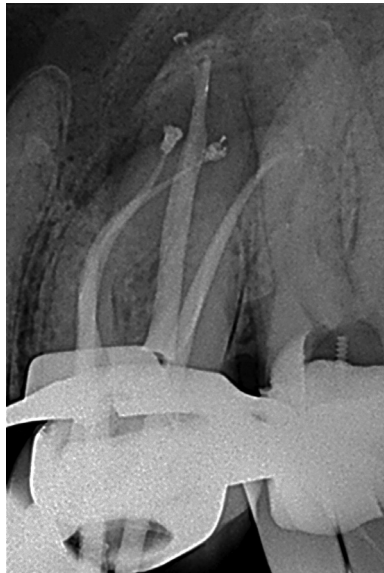**Figure 4a:** Preoperative radiograph of non-vital maxillary left first and second molars



**Figure 4b:** Length determination radiograph for the maxillary first molar



**Figure 6a:** Protaper Next X3 gutta percha cone and three size 020 Guttacore verifiers fitted to working lengths prior to obturation

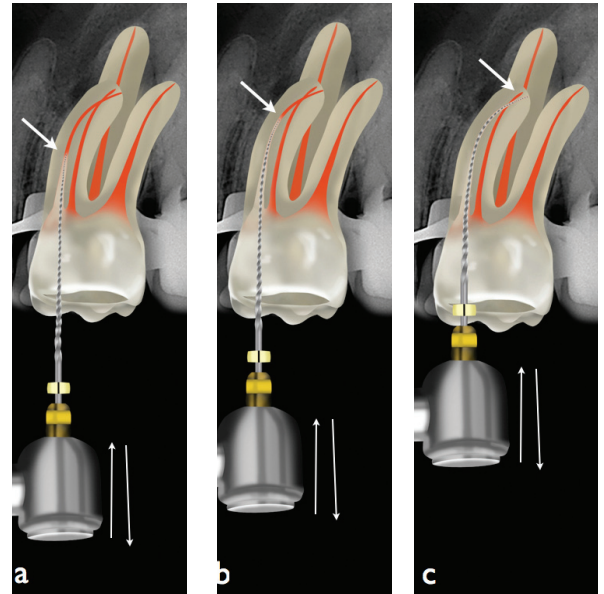


**Figure 6b:** Postoperative result after obturation

negotiate the canals in the mandibular second molar to full working length. A reproducible glide path was established in all the root canals and the glide paths enlarged to ISO 0.19mm using Pathfiles.

The coronal two thirds of the canals were prepared with Protaper Next X1 and X2 using a backstroke, outwards brushing motion to remove restrictive dentine in the canals, allowing the instruments to progress towards the apical third. The apical third of the root canals were prepared with a controlled push-pull motion, allowing the instruments to progress up to working length.

The prepared root canals were gauged with a size 25 nickel titanium hand file. The file was snug at working length except in the distal canal of the lower first molar. This canal was enlarged with a Protaper Next X3 instrument. Figure 3c shows radiographic confirmation of the working length and the fit of the plastic carriers of size 25 Protaper obturators (without gutta percha). All the canals were



**Figure 5a:** Protaper Next X1 is introduced into the canal and used in a push-pull motion. Restrictive dentine is removed on the outstroke, pulling motion. The push-pull motion was repeated a few times until the instrument progressed approximately 4mm (arrow). The instrument was removed from the root canal, the flutes cleaned and the canal irrigated, recapitulated and re-irrigated

**Figure 5b:** The file was reintroduced into the root canal and the same protocol repeated. The instrument now progressed up to the apical third of the root canal (arrow)

**Figure 5c:** The last cutting cycle carried the file up to working length (arrow)

obtured (Figure 3d) with size 25 Protaper obturators, except the distal root canal in the lower first molar that received a size 30 Protaper obturator. Figure 3e demonstrates the final result after obturation and Figure 3f illustrates healing of the periapical pathology around the roots on a six-month postoperative radiograph.

### Minimally invasive canal preparation

According to Gutmann (2013), minimally invasive endodontic (MIE) procedures can range from diagnosis to making a decision to treat (or not to treat) the case. They also include:

1. Minimal removal of dentine during access cavity preparation (Clark, Khademi, 2010), enlarging and shaping of the root canal system to retain as much as sound dentine as possible
2. Retention of tooth structure during disassembly and retreatment procedures.

We have to accept that if access openings are too restricted it can impact on the final result of treatment. Gutmann (2013) further suggests that efforts should be made to minimise the excess removal of cervical tooth structure in the canal orifice through the use of Peeso reamers, Gates Glidden burs and orifice opening instruments.

These instruments tend to straighten the canal and weaken the root canal walls, predisposing them to cracks and, in some cases, can even lead to root canal wall stripping defects. For some clinicians, it might be an option not to brush excessively with Protaper Next instruments but to rather use the 'push-pull' preparation technique.

### Case report

The patient, a 39-year-old male, presented with non-vital maxillary first and second molars (Figure 4a). He also reported that his previous dentist, for pain relief, did emergency root canal treatments on both teeth.

The temporary filling on the upper first molar was removed and four root canal orifices located and explored (mesiobuccal, mesiobuccal 2, distobuccal and palatal). Figure 4b shows a periapical radiograph confirming the working lengths that were electronically measured with the Propex Pixie apex locator (Dentsply/Maillefer).

Reproducible glide paths were established by using a size 10 K-file by hand, followed by mechanically enlarging the glide paths in all four root canals using Pathfiles no. 1, 2 and 3. All four root canals were prepared with Protaper Next using the following technique, resulting in minimally invasive canal preparations. In order to explain the technique, we will outline the preparation steps for one of the mesiobuccal root canals.

Protaper Next X1 was introduced into the canal and used in a push-pull motion. Restrictive dentine was removed on the outstroke, pulling motion. The push-pull motion was repeated a few times until the instrument progressed approximately 4mm (Figure 5a). The instrument was removed from the root canal, the flutes cleaned and the canal irrigated, recapitulated and re-irrigated. The file was re-introduced into the root canal and the same protocol repeated (Figure 5b). After three cutting cycles of 4mm each, the full working length was reached (Figure 5c).

ProTaper Next X2 was introduced and used following the same protocol. After two cutting cycles of 4mm each, full

working length was reached. A size 25/02 nickel titanium hand file was used to gauge the apical foramen. The file fitted snug at working length and shaping was complete.

The mesiobuccal, mesiobuccal 2, and distobuccal canals were prepared up to Protaper Next X2 and the palatal canal was prepared up to Protaper Next X3. Because the instruments were used in a push-pull motion instead of a deliberate brushing motion, the canal shapes were generally smaller in size and more conservative. The concept of larger apical sizes has been advocated to improve bacterial reduction. However, maintaining smaller sizes (>20<40) would seem desirable for the preservation of radicular dentine in the majority of cases and to rather focus on improved methods for cleaning and disinfecting root canal systems (Gutmann, 2013).

The palatal canal was obturated with a Protaper Next X3 gutta percha cone using the Calamus Dual Obturation Unit (Dentsply/Maillefer). It was decided to obturate the two mesiobuccal and distobuccal canals with Guttacore crosslinked gutta percha carries.

It must be noted that because of the more conservative canal preparations obtained with the push-pull preparation protocol it was not possible to passively fit a size X2 Guttacore verifier (size 025) up to working length in the prepared root canals. Only size 20 Guttacore verifiers fitted passively, without resistance to working length (Figure 6a). The selected root canals were then obturated using three size 20 Guttacore obturators. Figure 6b shows the final result after obturation. Carrier-based obturation also forms part of the MIE concept due to the minimal amount of application forces involved during the obturation process onto the remaining root structure. ■

### References

- Castellucci A (2005) Endodontics Volume II. (Eds) IL Tridente, Florence Italy
- Clark D, Khademi J (2010) Modern molar endodontic access and directed dentin conservation. *Dent Clin N Am* 54: 249-273
- Gutmann JL. Minimally invasive dentistry (Endodontics) (2013) *J Conserv Dent* 16: 282-283
- Gutmann JL, Gao Y (2012) Alteration in the inherent metallic and surface properties of nickel titanium root canal instruments to enhance performance, durability and safety: a focused review. *Int Endod J* 45: 113-128
- Ingle JI (2005) Root canal preparation. In: *PDQ Endodontics*. BC Decker, Hamilton, Ontario: 129
- Pruett JP, Clement DJ, Carnes DL (1997) Cyclic fatigue of nickel-titanium endodontic instruments. *J Endod* 23: 77-85
- Reuben J, Velmurugan N, Vasanthi S, Vijayalakshmi (2008) Endodontic management of a maxillary second premolar with an S-shaped root canal. *J Conserv Dent* 11(4): 168-170
- Scianamblo MJ. USPTO 6942484, 7094056, 7955078 and 20060228669. Attorney: Fish & Richardson P.C Current U.S Classification: 433/102, International Classification A61C005/02, 2011
- Van der Vyver PJ and Scianamblo (2013) Clinical guidelines for the use of ProTaper Next instruments: part one. *Endod Practice* 16(4): 33-40