Clinical guidelines for the use of Protaper Next instruments: part one

Peet van der Vyver and Michael J Scianamblo discuss the clinical guidelines for using Protaper Next instruments

CPD Aims and objectives

This clinical article aims to provide clinical guidelines for the use of Protaper Next instruments.

Expected outcomes

Correctly answering the questions on page xx, worth one hour of verifiable CPD, will demonstrate you understand how to use Protaper Next instruments.

Introduction

According to Bird, Chambers and Peters (2009), rotary nickel titanium instruments have become a standard tool for shaping root canal systems. These instruments provide the clinician with several advantages compared to conventional stainless steel instruments. For instance, they are more flexible, have increased cutting efficiency (Kim et al, 2012; Peters, 2004; Walia, Brantley, Gerstein, 1988), can create centred preparations more rapidly (Short, Morgan, Baumgartner, 1997; Glossen et al, 1995) and can produce tapered root canal preparations with a reduced tendency of canal transportation (Chen, Messer, 2002; Kim et al, 2012).

However, nickel titaumin instruments appear to have a high risk of fracture (Arens et al, 2003; Sattapan et al, 2000) mainly because of flexural and torsional stresses during rotation in the root canal system (Berutti et al, 2003; Parashos, Messer, 2006).

When there is a wide area of contact between the cutting edge of the instrument and the canal wall during rotation, the instrument will be subjected to an increase in torsional stress (Blum et al, 1999). The preparation of a reproducible glide path can reduce the torsional stress on root canal instruments. A glide path is a smooth passage that extends from the canal orifice in the pulp chamber to its opening at the apex of the root (West, 2006). This will provide a continuous, uninterrupted pathway for the rotary nickel titanium instrument to enter and to move freely to the root canal terminus.

The main purpose of a glide path is to create a root canal diameter the same size as, or ideally a size bigger than, the first rotary instrument introduced (Berutti et al, 2004; Varela-Patio et al, 2005; Berutti et al, 2009).

Another way to reduce torsional stress is to incorporate multiple progressive tapers to the instrument design for example the Protaper Universal system (Dentsply/Maillefer). According to West (2001), the progressive taper allows for only small areas of dentine to be engaged. This design concept also contributes to maintaining the original canal curvature (Yun, Kim, 2003).

Protaper Next

The Protaper Next system was recently launched into the dental market. There are five instruments in the system but most canals can be prepared by using only the first two.

This system also makes use of the multiple progressive taper concept. Each file presents with an increasing and decreasing percentage tapered design on a single file concept (Ruddle, Machtou, West, 2013). The design ensures that there is reduced contact between the cutting flutes of the instrument and the dentine wall, thus reducing the chance for taper lock (screw-in effect). At the same time, it also increases flexibility and cutting efficiency (Ruddle, 2001).

Figure 1

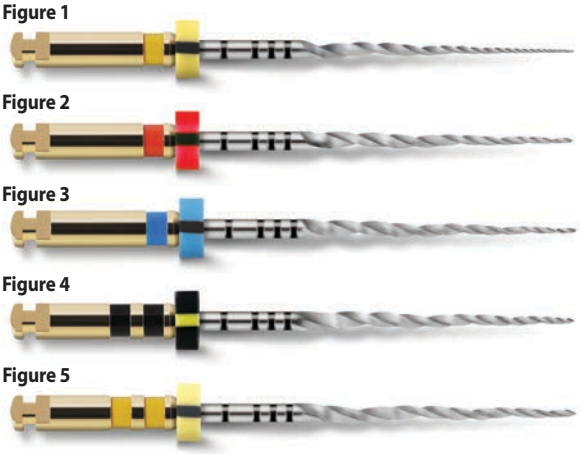

Figure 1: Protaper Next X1 (17/04) instrument
Figure 2: Protaper Next X2 (25/06) instrument
Figure 3: Protaper Next X3 (30/07) instrument
Figure 4: Protaper Next X4 (40/06) instrument
Figure 5: Protaper Next X5 (50/06) instrument

The first instrument in the system is Protaper Next X1 (Figure 1), with a tip size of 0.17mm and a 4% taper. This instrument is used after creation of a reproducible glide path by means of hand instruments or rotary Pathfiles. This instrument is always followed by the second instrument, the Protaper Next X2 (0.25mm tip and 6% taper) (Figure 2). Protaper Next X2 can be regarded as the first finishing file in the system, as it leaves the prepared root canal with adequate shape and taper for optimal irrigation and root canal obturation. Protaper Next X1 and X2 have an increasing and decreasing percentage tapered design over the active portion of the instruments.

The last three finishing instruments are Protaper Next X3

Peet J van der Vyver is extraordinary professor at the Department of Odontology, School of Dentistry, University of Pretoria and Private Practice, Sandton, South Africa.
Michael J Scianamblo DDS is an endodontist and the developer of Critical Path Technology. He is a postgraduate and fellow of the Harvard School of Dental Medicine and has served as a faculty member of the University of the Pacific and the University of California, Schools of Dentistry in San Francisco.



Figure 6: Protaper Next instruments have a bilateral symmetrical rectangular cross section (except last 3mm of X1) with an offset from the central axis of rotation (except in the last 3mm of all the instruments, D0-D3). This design characteristic allows the instrument to experience a rotational phenomenon known as precession or swagger. The swaggering movement enables the instrument to cut larger envelope of motion (red line) compared to a similarly sized instrument with a symmetrical mass and axis of rotation

(0.30mm tip with 7% taper) (Figure 3), Protaper Next X4 (0.40mm tip with 6% taper) (Figure 4) and Protaper Next X5 (0.5mm tip with 6% taper) (Figure 5). These instruments have a decreasing percentage taper from the tip to the shank. Protaper Next X3, X4 and X5 can be used to either create more taper in a root canal or to prepare larger root canal systems.

Another benefit of this system is the fact that the instruments are manufactured from M-wire and not traditional nickel titanium alloy. Research by Johnson et al (2008) demonstrated that the M-wire alloy could reduce cyclic fatigue by 400% compared to similar instruments manufactured from conventional nickel titanium alloys. The added metallurgical benefit contributes towards more flexible instruments, increased safety and protection against instrument fracture (Gutmann, Gao, 2012).

The last major advantage towards root canal preparation with the Protaper Next system is the fact that most of the instruments present with a bilateral symmetrical rectangular cross section (Figure 6) with an offset from the central axis of rotation (except in the last 3mm of the instrument, D0-D3). The exception is Protaper X1, which has a square cross section in last 3mm to give the instruments with a bit more core strength in the narrow apical part.

This design characteristic allows the instrument to experience a rotational phenomenon known as precession or swagger (Scianamblo, 2011). The benefits of this design characteristic include:

• It further reduces (in addition to the progressive tapered design) the engagement between the instrument and the dentine walls. This will contribute to a reduction in taper lock, screw-in effect and stress on the file

• Removal of debris in a coronal direction (Figure 7) because the off-centre cross-section allows for more space around the flutes of the instrument. This will lead to improved cutting efficiency, as the blades will stay in contact with the surrounding dentine walls. Root canal preparation is done in a very fast and effortless manner

• The swaggering motion of the instrument initiate activation of the irrigation solution during canal preparation, improving debris removal

• Reduced risk of instrument fracture because there is less stress on the file and more efficient debris removal

• Every instrument is capable of cutting a larger envelope of motion (larger canal preparation size) (Figure 6) compared to a similarly sized instrument with a symmetrical mass and axis of rotation. This allows the clinician to use fewer instruments to prepare a root canal to adequate shape and taper to allow for optimal irrigation and obturation

• There is a smooth transition between the different sizes of instruments because the design ensures that the instrument sequence itself expands exponentially.



Figure 7: Protaper Next instrument after canal preparation to full working length. Note the absence of debris on the cutting flutes in last 2-3mm of the instrument. In the presence of irrigation solution, the cutting debris is moved coronally, away from the tip of the instruments because of the swaggering effect allowing more space for fluid movement in the root canal system

Figure 8: Preoperative radiograph of maxillary left first premolar with three roots, showing a large periapical radiolucency

Clinical guidelines for Protaper Next instruments

The clinical technique for Protaper Next will be discussed by means of case reports. The first case report will outline the basic guidelines for the use of Protaper Next instruments.

The patient, a 64-year-old male, presented with a previous emergency root canal treatment on his upper left first premolar. A periapical radiograph showed evidence of three separate roots and large periapical lesion (Figure 8). According to the patient, the tooth was left open by his dentist who had performed the emergency root canal treatment to allow for drainage.

Guideline one: create straight-line access and remove triangles of dentine

It is very important to prepare an adequate access cavity that will ensure straight-line access into each root canal system.

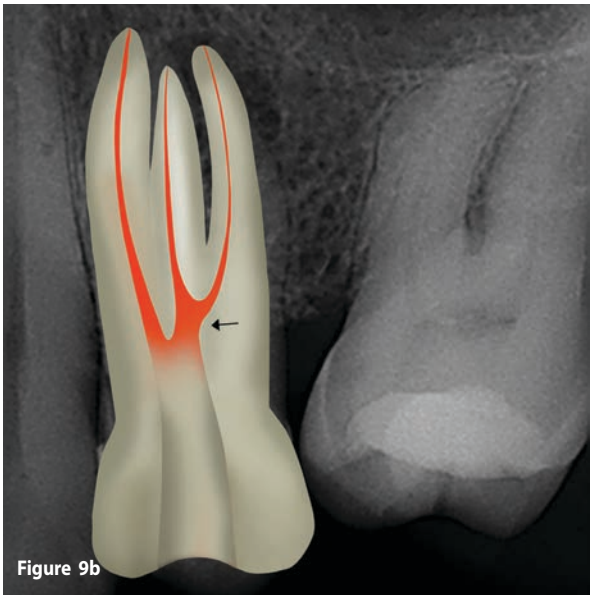

Figures 9a and 9b: Extended access cavity preparation to allow straight-line access into the buccal and palatal root canals. Arrows indicate dentine triangle obscuring the orifice of the distobuccal root canal

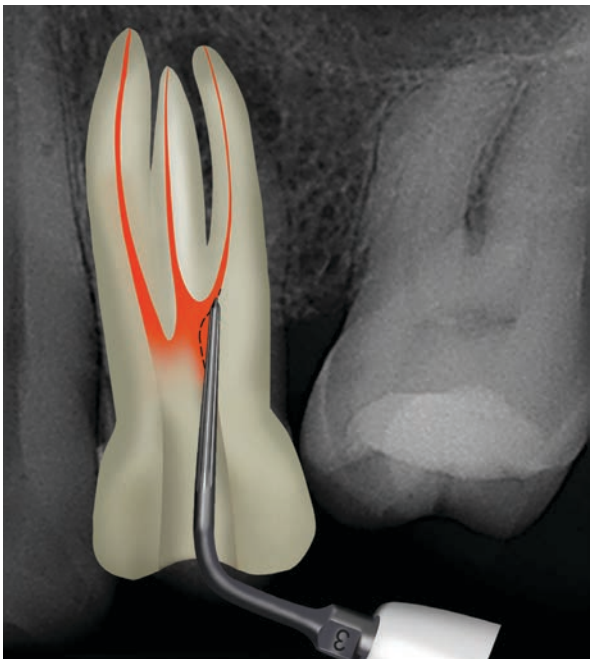

Figure 10: Start-X tip no. 3 is used to remove some of the restrictive dentine obscuring the distobuccal canal

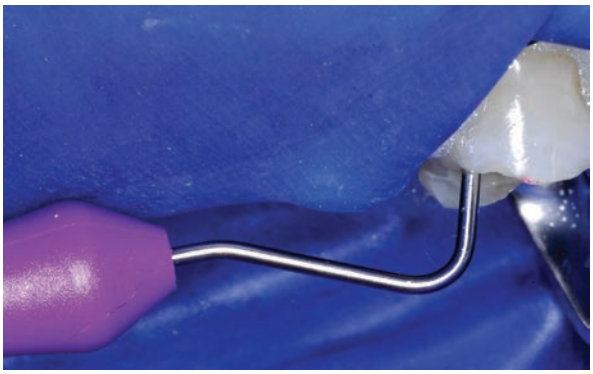

Figure 11: Micro-opener (Dentsply/Maillefer), size 10, taper 6% is used to locate the distobuccal canal orifice

However, in the present clinical case there was still a dentine triangle obscuring direct access into the distobucaal root canal system (Figures 9a and 9b). The Start-X tip no. 3 was used to remove some of this dentine on the pulp floor (Figure 10), allowing more direct access to the distobuccal root canal orifice.

A Micro-opener (Dentsply/Maillefer) – size 10, 06% taper – instrument was used to locate and enlarge the distobuccal and mesiobuccal canal orifices (Figure 11). For improved radicular access, the SX instrument (Dentsply/Maillefer) from the Protaper Universal system was used (Figure 12a). The recommended method of use is to introduce the file into the coronal portion of the root canal, ensuring that the file is able to freely rotate. Restrictive dentine is then removed by using a back-stroke, outwards brushing motion. This step will also relocate the canal orifices more mesial or distal (away from furcal danger) and preflare the canal orifices, ensuring complete staight-line access into the root canal system (Figure 12b).

Guideline two: negotiate canal to patency and create a reproducible glide path

The authors prefer to negotiate the root canal with size 08 or 10 K-files until apical patency is established (Figure 13a). Apical patency is the ability to pass small K-files (0.5-1mm) passively through the apical constriction, beyond the minor diameter without widening it (Buchanan, 1989). Length determination was done using a Propex Pixi apex locator (Dentsply/Maillefer). Predictable readings were achieved by using two size 10 K-files in the mesiobuccal and distobuccal root canals and a size 20 K-file in the larger palatal root canal and confirmed radiographically (Figure 13b).

After working length determination, a reproducible glide path should be established. It is recommended to use the stainless steel K-files in vertical in and out motion with an amplitude of 1mm and gradually increase the amplitude as the dentine wall wears away and the file advances apically (West, 2006). West (2010) recommends a 'super loose' size 10 K-file as the minimum requirement. To confirm that a reproducible glide path is present, the size 10 file is taken to full working length (Figure 14a). The file is then withdrawn 1mm and should be able to slide back to working length by using light finger pressure. Thereafter, the file is withdrawn 2mm and should be able to slide back to working length,

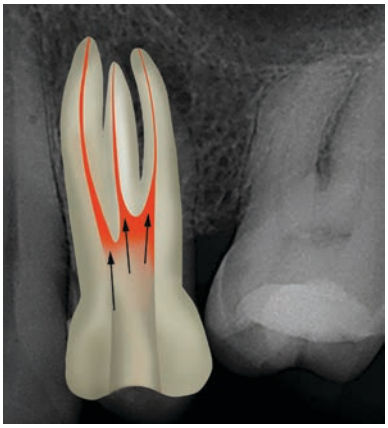

Figure 12a: Protaper SX instrument (Dentsply/Maillefer) instrument is used to create more straight-line radicular access

Figure 12b: Direct, straight-line access (arrows) into all three canals after removal of coronal restrictive dentine

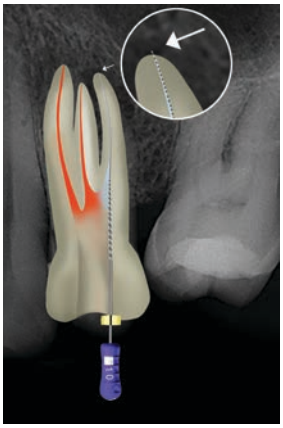

Figure 13a: Distobuccal root canal negoitiated to patency (arrow) with a size 10 K-file (Dentsply/Maillefer)

Figure 13b: Periapical radiograph showing the position of the files during length determination – two size 10 K-files in mesiobuccal and distobuccal root canals and a size 20 K-file in palatal root canal

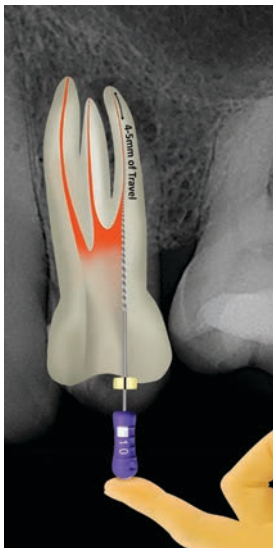

Figures 14a and 14b: Reproducible glide path confirmation. Figure 14a shows a size 10 K-file is taken to full working length. Figure 14b shows a size 10 K-file withdrawn 4mm to 5mm and slid back to working length using light finger pressure

using the same protocol. When the file can be withdrawn 4mm to 5mm and slid back to working length (Figure 14b), a reproducible glide path is confirmed (Van der Vyver, 2011).

The reproducible glide path is then enlarged using rotary Pathfiles (Dentsply/Maillefer). Pathfile no. 1 (0.13mm tip size) is taken to full working length, operating at 300rpm and 5N/cm torque (Figure 15a). As soon as the file reaches working length, the authors recommend to brush lightly outwards against one side of the canal wall. The file is pushed back to working length and brushed outward against another part of the canal wall. This procedure is repeated four times (touching the canal wall in a mesial, distal, buccal and lingual direction). Pathfile no. 2 (0.16mm tip size) is used following the same protocol (Figure 15b). When using Protaper Next, it is only necessary (in most cases) to enlarge the glide path to the second Pathfile (0.16mm) as the first preparation instrument, the X1 of the Protaper Next system has a tip size of ISO 17. However, it is recommended to use Pathfile no. 3 (0.19mm tip size) when dealing with challenging root canal systems.

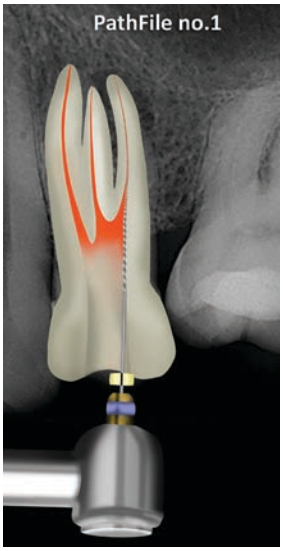

Figure 15a: Pathfile no. 1 is taken to full working

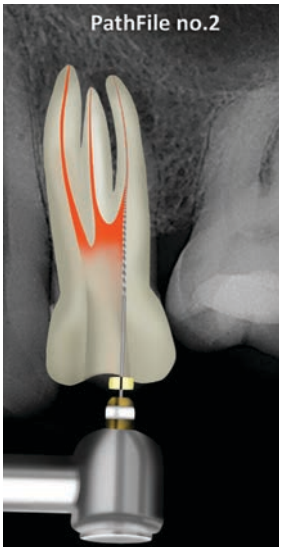

Figure 15b: Pathfile no. 2 is taken to full working length

Guideline three: Protaper Next preparation sequence

Introduce sodium hypochlorite and the Protaper Next X1 instrument into the root canal. The authors found that four scenarios can present when using the Protaper Next X1 instrument:

1. Easy root canals
2. More difficult and longer root canals
3. Very long/severely curved root canals
4. Larger diameter root canals and retreatment cases root canals where the use of Protaper Next X1 is not necessary and canal preparation can be initiated with Protaper Next X2, X3, X4 or X5. The last two scenarios will be discussed later in this article.

For easy canals (mesiobuccal root canal in this case report), allow the Protaper Next X1 instrument (operating at 300rpm and torque of 2.8N/cm) to slide down the glide path up to working length (Figure 16a). If this is possible, pull the instrument back to approximately 2-3mm short of working length and incorporate a deliberate backstroke, outward brushing motion (away from any external root concavities) to create more space in the coronal aspect of the root canal (Figure 16b). Finally, take the file to full working

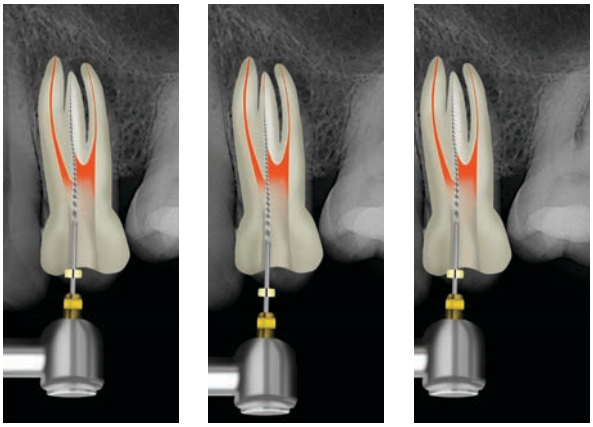

Figures 16a-c: Preparation sequence for easy canals. Figure 16a shows Protaper Next X1 (operating at 300rpm and torque of 2.8N/cm) slided down the glide path and able to reach working length. Figure 16b shows the instrument pulled back to approximately 2-3mm short of WL and a deliberate backstroke, outward brushing motion incorporated (away from any external root concavities) to create more space in the coronal aspect of the root canal. Figure 16c shows the instrument taken to full WL and a 'touch-and-brush' sequence done three to four times in order to complete canal preparation

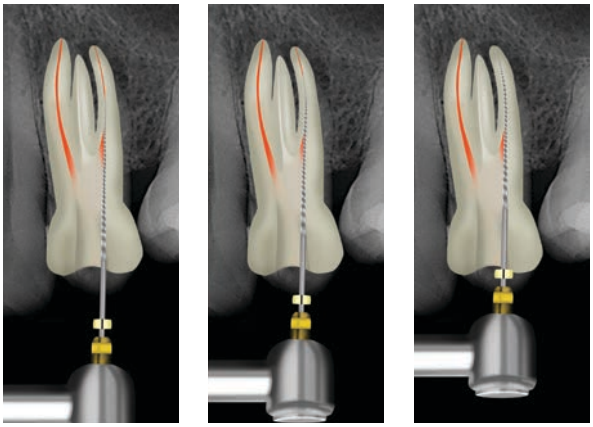

Figures 17a-c: Preparation sequence for more difficult or longer canals. Allow the Protaper Next X1 to slide down the glide path until resistance is met. Incorporate a deliberate backstroke, outward brushing motion in order to remove restrictive dentine at this level at this level (Figure 17a). Increased lateral space will enable the file to slide a few more millimetres down the root canal towards working length and the brushing cycle is repeated (Figure 17b). When the file reaches full WL, the 'touch-and-brush' sequence is done three to four times to complete canal preparation (Figure 17c)

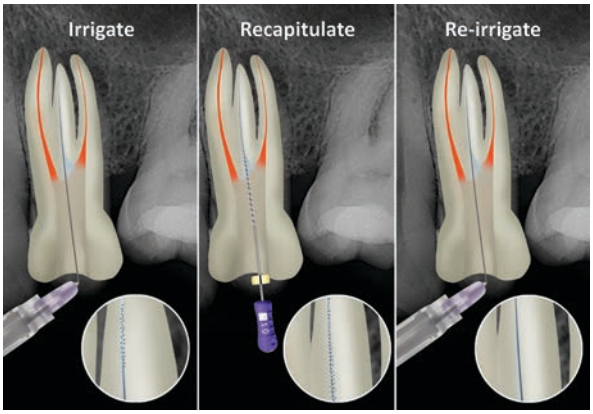

Figures 18a-c: Irrigation solution is deposited into the root canal before a patency file is used to dislodge any debris inside the root canal. Finally, the dislodged debris is flushed out with fresh irrigation solution

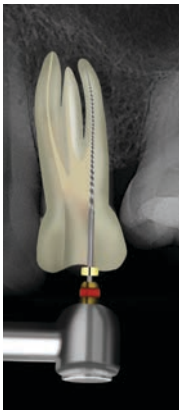

Figure 19: Protaper Next X2 is taken to full WL. The apical part of the root canal is prepared by using the 'touch-and-brush' sequence only two to three times with this instrument

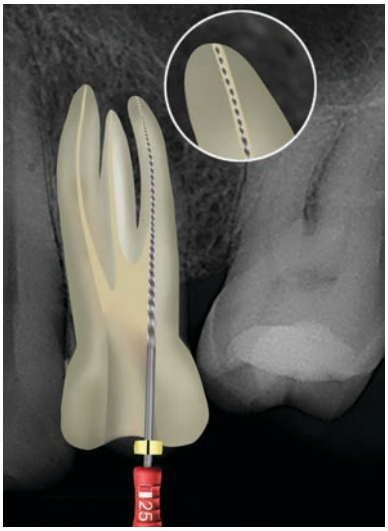

Figure 20: Size 25/02 nickel titanium hand file is used to gauge the apical foramen of the prepared distobuccal root canal. Note that the file fits snug up to the full WL

length and 'touch' the apex and brush outwards (coronally) with the file in the apical third of the root canal. This 'touch-and-brush' sequence can be repeated up to three or four times (Figure 16c).

For more difficult and longer canals (distobuccal root canal in this case report), allow the Protaper Next X1 to slide down the glide path until resistance is met (Figure 17a). Incorporate a deliberate backstroke, outward brushing motion in order to remove restrictive dentine at this level (away from any external root concavities). This motion will create more lateral space, enabling the file to slide a few more millimetres down the root canal towards working length (Figure 17b) (if the file ceases to progress apically, remove the file, clean the flutes, irrigate, recapitulate and re-irrgate the canal before you progress with the shaping procedure). This procedure is repeated until the file reaches full working length. Finally, take the file to full working length (Figure 17c) and the 'touch-and-brush' sequence is done three to four times in order to complete canal preparation.

After the use of Protaper Next X1, it is recommended to irrigate with sodium hypochlorite, recapitulate with a small patency file to dislodge cutting debris and to re-irrigate to flush out all the dislodged debris from the root canal (Figures 18a-c).

Protaper Next X2 (first finishing instrument)

Use Protaper Next X2 (25/06) to full working length, using the same protocol as described above. However, it is recommended to use the 'touch-and-brush' sequence in the apical part of the root canal only two to three times as a final step (Figure 19). Excessive 'touch-and-brush' sequences in the apical part of the root canal can lead to transportation of the root canal. The root canal is again irrigated, recapitulated and re-irrigated.

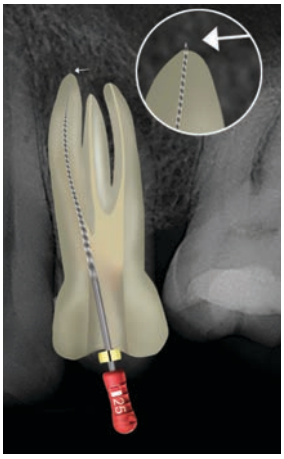

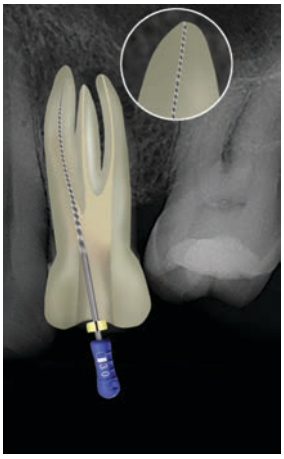

Figure 21a: Size 25/02 NiTi hand file is used to gauge the apical foramen of the prepared palatal root canal. In this case it was found that the 25/02 file was loose at length and it could be pushed past working length (arrow)

Figure 21b: A size 30/02 NiTi hand file that fit snug at working length, confirmed that the shape is complete

Figure 22a: A 30/02 NiTi hand instrument fit tight and short of the full working length (arrow)

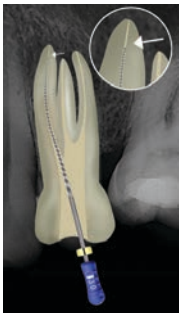

Figure 22b: Continue shaping with a Protaper Next X3 (30/07) to full working length

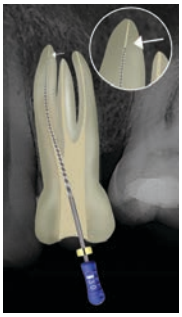

Figure 22c: Gauge again with a 30/02 NiTi hand instrument. If the instrument fits tight and at full working length the shape is complete

Figure 23: Final result after obturation using the Calamus Dual Obturation Unit (Dentsply/ Maillefer)

Figure 24: Preoperative radiograph of mandibular right first molar. Note the dentine triangle (arrow) preventing straight-line access into the mesial root canals

Figure 25: Access cavity preparation after the tooth was restored with composite. Note the evidence of the dentine triangles on the mesial aspect of the canal orifices

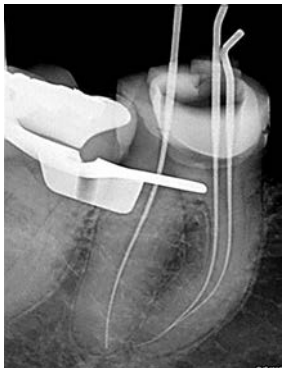

Figure 26: Length determination radiograph showing striaghtline access of the K-Files into all the root canal systems

Gauging of apical foramen to determine if the preparation is complete

Introduce a size 25/02 nickel titanium hand file (Dentsply/ Maillefer) to full working length (Figure 20). If the file is snug at working length it means that the apical foramen is prepared to a size ISO 25 and the canal is adequetley shaped.

The palatal root canal in the present case report was prepared with the Protaper Next X1 and X2, according to the protocol outlined above. In this case it was found that the 25/02 nickel titanium hand file was fitting loose at length and it could be pushed past working length (Figure 21a) after canal preparation with the X2 instrument. This indicated that the apical foramen was still larger than 0.25mm. In these situations, it is recommended to gauge the foramen with a size 30/02 nickel titanium hand file (Figure 21b). If the 30/02 file is snug at length, the shape is complete.

If it is found that the 30/02 instrument fits tight, but short of the full working length (Figure 22a), it is recommended to continue canal preparation with the Protaper Next X3 (30/07) (Figure 22b) and gauge again with the 30/02 nickel titanium hand instrument (Figure 22c).

Guideline four: shaping recommendations for Protaper Next X3, X4 and X5

Protaper Next X3 (as well as X4 and X5 if necessary) is used in the same manner as Protaper X1 or X2 with the exception that the apical preparation is done by using the 'touch-and-brush' sequence only once or twice in the apical third of the root canal. Apical gauging is done according to the above mentioned protocol using a size 30/02, 40/02 or 50/02 nickel titanium instruments.

The 30/02 instrument was fitting snug at working length in the palatal root canal in the present case report. The canals were obturated with Protaper Next X2 gutta percha points in the mesiobuccal and distobuccal root canals and a Protaper Next X3 gutta percha point in the palatal root canal as master cones using the Calamus Dual Obturation Unit (Dentsply/maillefer). Figure 23 demonstrates the final result after canal obturation.

Preparation sequence for very long and curved root canals

In selected clinical cases, the clinician might find that Protaper Next X1 does not progress to full working length even after a few coronal circumferential brushing motions. The authors then recommend to create more coronal shape by using Protaper Next X1 followed by Protaper Next X2 up to two thirds of the canal length. This preparation sequence will create enough lateral space in the coronal two thirds of the root canal to ensure that Protaper Next X1 can now be taken to full working length without any difficulty.

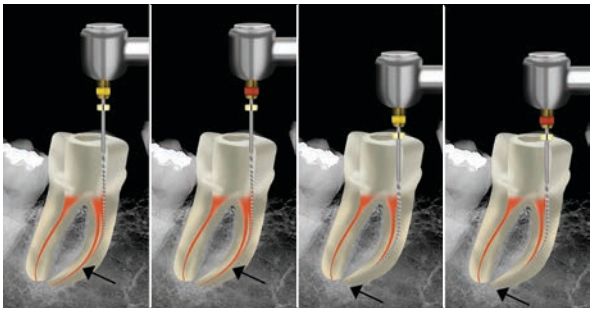

Figure 27a: Protaper Next X1 (with outstroke brushing motion) is used to secure the coronal two thirds of the canal length
Figure 27b: After irrigation, recapitulation and re-irrigation sequence with sodium hypochlorite the Protaper Next X2 is then used in the same manner to secure the the canal to the same length
Figure 27c: Protaper Next X1 is then used until the file can progress to full working length
Figure 27d: After irrigation, recapitulation and re-irrigation, Protaper Next X2 is thereafter taken to full working length

Figure 28a: Guttacore verifiers fitted to WL to confirm the size of obturators needed after the canals were preparared with Protaper Next

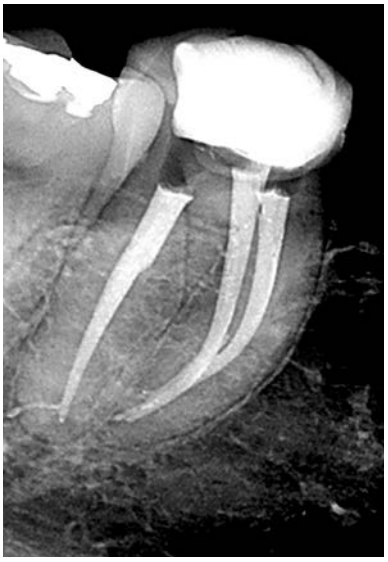

Figure 28b: Postoperative result after the canals were obturated with Guttacore obturators

Case report

The patient, a 50-year-old female, presented with pain on her mandibular rigth first molar with a history of previous emergency root canal treatment. Clinical examination revealed a broken down and leaking temporary restoration, possibly resulting in coronal leakage. A periapical radiograph revealed very long and curved mesial roots. Also visible on the radiograph was evidence of dentine triangles, preventing straight-line access into the mesial root canals (Figure 24).

The defective temporary restoration and caries were removed before the tooth was restored with composite and a new access cavity prepared. Note the evidence of dentine triangles on the mesial aspect of the canal orifices (Figure 25). The dentine triangles were removed with a Protaper SX instrument, ensuring straight-line access into all the root canals. Figure 26 shows the radiographic view of the length determination confirming straight-line access into the root canals.

As mentioned before, the clinical protocol for cases with very long and curved root canals would be to allow Protaper Next X1 to progress to about two thirds of the canal length (Figure 27a). This is followed by irrigation, recapitulation and re-irrigation sequence with sodium hypochlorite. Protaper Next X2 is then used in the same manner (with circumferential outstroke brushing motions) to the same length (Figure 27b). Protaper Next X1 is then used again to progress with canal preparation to full working length (Figure 27c) using the 'touch-and-brush' sequence as described before. Protaper Next X2 is taken to full working length (using the same protocol as decribed before) (Figure 27d) after irrigation, recapitulation and re-irrigation of the root canal.

Canals were gauged according to the technique described before and final preparation was done up to Protaper Next X2 in the mesial root canals and up to Protaper Next X3 in the distal root canal. Guttacore verifiers were fitted (Figure 28a) to working length to confirm the size of obturators for each canal before the canals were obturated with corresponding Guttacore obturators. Figure 28b shows the postoperative result after obturation.

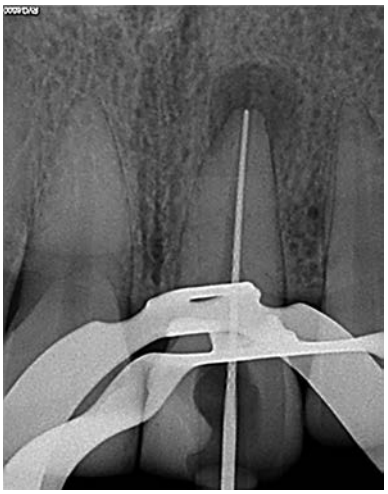

Figure 29a: Preoperative radiograph of the maxillary right central incisor revealed a previously underfilled root canal treatmeant and there was evidence of a large periapical area

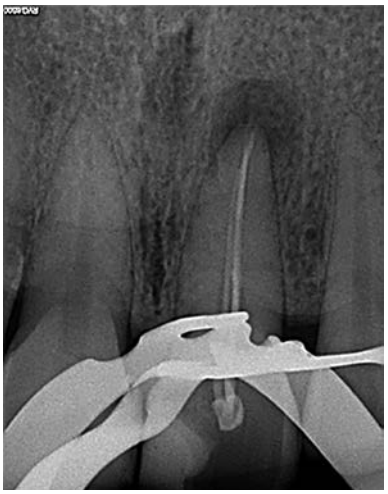

Figure 29b: Length determination, using a size 35 K-file

Shaping recommendations for large diameter root canals or retreatment of root canals

If the first file to working length is a size 20 K-file and it is loose up to working length, the shaping procedure can be initiated by using Protaper Next X2 (25/06). If the first files to length are a size 25/30, 30/35 or 40/45 and they are found to be loose in the canal up to working length, the shaping procedure can be initiated with Protaper Next X3 (30/07), X4 (40/06) and X5 (50/06) respectively.

Case report

The patient, a 44-year-old female, presented with pain and discomfort on her maxillary right central incisor. Radiographic examination revealed that the tooth was poorly root treated and there was evidence of a large periapical area (Figure 29a). After removal of the previous gutta percha, it was possible to take a size 35 K-file to working length (Figure 29b).

Root canal preparation was initiated by preparing the root canal to working length with the Protaper Next X4 (40/06)

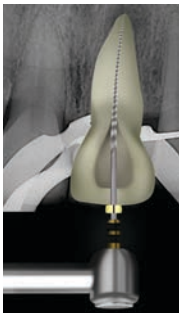

Figure 30a: Protaper Next X4 intrument taken to full WL

Figure 30b: Apical gauging with a 40/02 NiTi hand file revealed the tip of the file was loose at length and able to travel past the predetermined WL

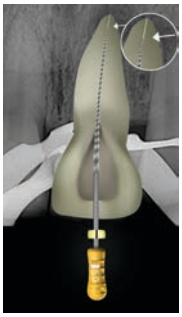

Figure 30c: Apical gauging with a size 50/02 NiTi hand file was unable to reach full working length, penetrating to about 2mm short of WL

Figure 31a: After irrigation, recapitulation and re-irrigation, a Protaper Next X5 was taken to full WL

Figure 31b: Apical gauging with a size 50/02 NiTi hand file. The file was snug at WL

Figure 31c: Postoperative result after the root canal obturation

instrument (Figure 30a). Apical gauging with a 40/02 nickel titanium hand file revealed that the tip of the file was loose at length and able to travel past the predetermined working length (Figure 30b) and that a size 50/02 nickel titanium hand file was unable to reach full working length, penetrating to about 2mm short of working length (Figure 30c). This indicated that the apical foramen size was between 0.40mm and 0.50mm. The root canal preparation was enlarged with an Protaper Next X5 (50/06) (Figure 31a) and gauged again with a 50/02 hand nickel titanium file. It was found that the 50/02 instrument fitted snug at working length (Figure 31b) indicated that the shape was complete. The prepared canal was obturated with a Protaper Next X5 gutta percha point using Calamus Dual Obturation Unit. Figure 31c show the final result after obturation.

Part two of this series will discuss the management of complex root canal systems with the Protaper Next system.

References

Arens FC, Hoen MM, Steinman HR, Dietz GC Jr. (2003) Evaluation of single-use rotary nickel-titanium instruments. *J Endod* 29: 664-666

Berutti E, Cantatore G, Castellucci A, Chiandussi G, Pera F, Migliaretti G, Pasqualini D (2009) Use of nickel-titanium rotary Pathfile to create the glide path: comparison with manual preflaring in simulated root canals. *J Endod* 35: 408-12

Berutti E, Chiandussi G, Gaviglio I, Abba A (2003) Comparative analyses of torsional and bending stresses in two mathemathecal models of nickel-titanium rotary instruments: ProTaper vesus Profile. *J Endod* 29:15-19

Berutti E, Negro AR, Lendini M, Pasqualini (2004) Influence of manual preflaring and torque on the failure rate of ProTaper rotary instruments. *J Endod* 30: 228-30

Bird DC, Chambers D, Peters OA (2009) Usage parameters of nickel titanium rotary instruments: a survey of endodontics in the United States. *J Endod* 35:1193-1197

Blum JY, Cohen P, Machtou P, Micallet JP (1999) Analysis of forces developed during mechanical preparation of extracted teeth using Profile NiTi rotary instruments. *Int Endod J* 32:24-31

Buchanan LS (1998) Management of the curved root canal. *J Calif Dent Assoc* 17: 18-27

Chen JL, Messer HH. Comparison of stainless steel hand and rotary nickel-titanium instrumentation using a silicone impression technique. *Aust Dent J* 2002; 47:12-20

Glossen CR, Haller RH, Dove SB, del Rio CE (1995) A comparison of root canal preparations using Ni-Ti engine-driven, and K-Flex endodontic instruments. *J Endod* 21:146-151

Gutmann JL, Gao Y (2012) Alteration in the inherent metallic and surface properties of nickel titanium root canal instruments to enhance performance, durability and safety: a focused review. *Int Endod J* 45:113-128

Johnson E, Lloyd A, Kuttler S, Namerow K (2008) Comparison between a novel nickel-titanium alloy and 508 nitinol on the cyclic fatigue of Profile 25/.04 rotary instruments. *J Endod* 34: 1406-1409

Kim H-C, Kwak S-W, Cheung Gs-P, Ko D-H, Chung S-M, Lee W (2012) Cyclic fatigue and torsional resistance of two new nickel-titanium instruments used in reciprocation motion. Reciproc versus WaveOne. *J Endod* 38:541 544

Parachos P, Messer HH (2006) Rotary NiTi instrument fracture and its consequences. *J Endod* 32:1031-1043

Peters OA (2004) Current challenges and concepts in the preparation of root canal systems: a review. *J Endod* 30:559-567

Ruddle CJ (2001) The ProTaper endodontic system: geometries, features, and guidelines for use. *Dent Today* 10: 60-67

Ruddle CJ, Machtou P, West JD (2013) The shaping movement: Fifth-generation technology. *Dent Today* 32(4): 94, 96-99

Sattapan B, Nervo GJ, Palmara JF, Messer HH (2000) Defects in nickel-titanium files after clinical use. *J Endod* 26: 161-165

Scianamblo, MJ. USPTO 6942484, 7094056,7955078 and 20060228669. Attorney: Fish & Richardson P.C Current U.S Classification: 433/102, International Classification A61C005/02, 2011

Short JA, Morgan IA, Baumgartner JC (1997) A comparison of canal centering ability of four instrumentation techniques. *J Endod* 23: 503-507

Van der Vyver PJ (2011) Creating a glide path for rotary NiTi instruments: Part one. *Endod Practice* 14(1): 40-43

Varela-Patiňo P, Martin-Biedma B, Rodriguez LC, Cantatore G, Bahillo JG (2005) The influence of a manual glide path on the separation rate of Ni-Ti rotary instruments. *J Endod* 31: 114-6

Walia H, Brantley WA, Gerstein H (1988) An initial investigation of the bending and torsional properties of nitinol root canal files. *J Endod* 14:356-351

West JD (2001) Introduction of a new rotary endodontic system: progressively tapered files. *Dent Today* 20:5; 50-57.

West J (2006) Endodontic update. *J Esthet Restor Dent* 18: 280-300

West J (2010) The endodontic glide path: "Secret to ratary safety". *Dent Today* 29:86-93

Yun HH, Kim SK (2003) A comparison of the shaping abilities of four nickel-titanium rotary instruments in simulated root canals. *Oral Surg Oral Med Oral Pathol Oral Radiol Endod* 95:228-233