Root Canal Preparation of Mandibular Molars with 3 Nickel-Titanium Rotary Instruments: A Micro–Computed Tomographic Study

Dan Zhao, DDS, [*] *Ya Shen, DDS, PhD,* [†‡] *Bin Peng, DDS, PhD,* [*] *and Markus Haapasalo, DDS, PhD* [†]

Abstract

Introduction: The aim of this study was to describe the canal shaping properties of ProTaper Next (PTN; Dentsply Maillefer, Ballaigues, Switzerland), ProTaper Universal (PTU; Dentsply Tulsa Dental Specialties, Johnson City, TN), and WaveOne (Dentsply Maillefer) nickel-titanium instruments in mandibular first molars by using micro–computed tomographic (micro-CT) scanning. **Methods:** A total of 36 maxillary first molars with 2 separate mesial canals and 1 distal canal were selected and scanned preoperatively and postoperatively by using micro-CT scanning with a voxel size of 30 μm. Canals were prepared with PTU, PTN, and WaveOne systems under hypochlorite irrigation. The volume of the untreated canal; the volume of dentin removed after preparation; the amount of the uninstrumented area; and the transportation to the coronal, middle, and apical thirds of canals were measured. The preparation time and instrument failure were also recorded. **Results:** Instrumentation of canals increased their volume and surface area. The distal canals had a significantly higher proportion of unprepared surfaces than mesial canals ($P < .05$). The PTN system produced less transportation than the WaveOne and PTU systems in the apical third of the mesial canals ($P < .05$). There was no significant difference on apical transportation in distal canals among the 3 instrument systems. Instrumentation with WaveOne was significantly faster than with the other 2 instruments ($P < .05$). **Conclusions:** The PTN, PTU, and WaveOne instruments shaped root canals in mandibular first molars *in vitro* without significant shaping errors. The curved canals prepared using PTN had less apical transportation than the canals prepared using WaveOne and PTU. *(J Endod 2014;40:1860–1864)*

Key Words

Micro–computed tomographic scanning, nickel-titanium instrument, ProTaper Next, ProTaper Universal, WaveOne

Over the decades, a wide array of nickel-titanium (NiTi) instruments has been introduced for shaping root canals (1). Since their first appearance, instrument design has changed considerably; progress has been made in design as well as in alloy processing (2, 3). The development of new files nowadays is a fast and market-driven process. Clinical procedures and ideal working parameters are still being refined as new instruments continue to be introduced to the market. With new versions rapidly becoming available, the clinician may find it difficult to choose the file and technique most suitable for an individual case.

In 2011, WaveOne (Dentsply Maillefer, Ballaigues, Switzerland) was introduced as a single-file technique. These files are made of a special NiTi alloy called M-Wire that is created by a thermal treatment process. The benefits of M-Wire NiTi are increased flexibility of the instruments and improved resistance to cyclic fatigue (4, 5). The WaveOne system is designed to be used with a dedicated reciprocating motion motor. It consists of 3 single-use files: small (ISO 21 tip and 6% taper) for small canals, primary (ISO 25 tip and 8% taper) for the majority of canals, and large (ISO 40 tip and 8% taper) for large canals. ProTaper Next (PTN, Dentsply Maillefer) is a novel set of rotary instruments based on the convergence of a variable taper design on a given file (ProTaper Universal [PTU], Dentsply Tulsa Dental Specialties, Johnson City, TN), M-Wire technology, and an offset mass of rotation. The set includes 5 shaping instruments with variable tapers; at the tip, X1 is #17/.04, X2 is #25/.06, X3 is #30/.075, X4 is #40/.06, and X5 is #50/.06. All the instruments are expected to follow the canal passively until the working length (WL) is achieved. With these new NiTi systems, investigations of their shaping effect are becoming more important to understand how the design features and different kinematics affect their performance.

Canal anatomy influences preparation outcomes; significantly more aberrations are recorded when preparing simulated canals with more acute curves in plastic blocks using various NiTi rotary instruments (6). The technique of micro–computed tomographic (micro-CT) scanning allows a complete description of the 3-dimensional effects that root canal preparation exerts on root canal anatomy without altering the root (7). This research tool allows nondestructive quantitative analyses of different variables such as volume, surface area, cross-sectional shape, and the proportion of the prepared surface (8–10). Therefore, the aim of this study was to quantitatively

From the *Division of Endodontics, State Key Laboratory Breeding Base of Basic Science of Stomatology (Hubei-MOST) and Key Laboratory of Oral Biomedicine Ministry of Education, School and Hospital of Stomatology, Wuhan University, Wuhan, China; †Division of Endodontics, Department of Oral Biological and Medical Sciences, Faculty of Dentistry; and ‡Department of Materials Engineering; The University of British Columbia, Vancouver, Canada.

Address requests for reprints to Prof Bin Peng, State Key Laboratory Breeding Base of Basic Science of Stomatology (Hubei-MOST) and Key Laboratory of Oral Biomedicine Ministry of Education, School and Hospital of Stomatology, Wuhan University, 237 Luoyu Road, Wuhan 430079, PR China. E-mail address: phs301@vip.163.com

0099-2399/$ - see front matter

http://dx.doi.org/10.1016/j.joen.2014.06.023

assess canal preparation outcomes achieved by the single-file WaveOne technique under reciprocating movement, the PTN technique, and conventional PTU instruments with continuous rotation. Micro-CT scanning was used to compare the following parameters in extracted human mandibular molars with 2 separate mesial canals and 1 distal canal: changes in dentin volume, percentage of shaped canal walls, and degree of canal transportation. In addition, the time used for canal instrumentation with each system was recorded.

Materials and Methods

Selection and Preparation of Specimens

Thirty-six similar extracted mandibular first molars that had 3 separate canals with complete root formations were collected under a protocol approved by the local ethics committee of the university. The teeth were externally cleaned with pumice and then stored in 0.01% sodium hypochlorite (NaOCl) at 4°C before use. The pulp chambers were accessed conventionally. Size 10 K-files (Dentsply Maillefer) were inserted through the mesiobuccal and mesiolingual canals (2 separated canals all the way to the apex) 1 mm beyond the apical foramen to establish apical patency. Canal lengths were determined with size 10 K-files and radiographs. The WL was established 1 mm shorter than the apical foramen. A custom-made mold for each tooth was made with a self-curing resin to facilitate mounting of the tooth.

Root Canal Instrumentation

The angle of curvature of all molars used in this study was 25°–35°, 15°–25°, and 5°–20° in the mesiobuccal, mesiolingual, and distal canals, respectively, according to the method of Schneider (11). Care was taken to divide the specimens equally into 3 groups with respect to canal curvatures. Curvatures were judged from digital radiographs and determined quantitatively using micro-CT data (Table 1).The teeth were randomly divided into 3 equal groups (n = 12). Teeth in each group were instrumented with 1 of the following three instruments: WaveOne, PTN, or PTU. PTU and PTN instruments were set into permanent rotation with a 6:1 reduction handpiece powered by the X-Smart Plus endodontic motor (Dentsply Maillefer). For PTN and PTU files, the individual torque limit and rotational speed were set according to the manufacturers' recommendation, whereas WaveOne was used in a reciprocating working motion generated by the motor. The preparation sequences were as follows:

1. *WaveOne group:* For mesial root canals, a primary reciprocating WaveOne file #25/.08 was used, whereas a WaveOne file #40/.06 was used for distal root canals. Files were used in a reciprocating, slow in-and-out pecking motion according to the manufacturer's instructions. The flutes of the instrument were cleaned after 3 pecks (12).
2. *PTU group:* All canals were instrumented/inspected to size #20 (or #15) hand K-files before the use of rotary files. Mesial root canals were prepared with 4 PTU rotary instruments in the sequence recommended by the manufacturer (S1, S2, F1, and F2). For distal root canals, canal shaping was performed with ProTaper S1-S2-F1-F2 and enlargement with F3 and F4 (13).
3. *PTN group:* All canals were instrumented/inspected to size #15 hand K-files before the use of rotary files. Mesial root canals were shaped with PTN X1 (#17/.04)-X2 (#25/.06) at the WL. For distal root canals, canal shaping was performed with PTN X1 (#17/.04)-X2 (#25/.06) and then enlargement with X3 (#30/.07) and X4 (#40/.06) according to the manufacturer's instructions (14).

The pulp chamber was filled with 5.25% NaOCl throughout the instrumentation, and 2 mL 5.25% NaOCl was used to irrigate the canal

TABLE 1. Preoperative Canal Volume, Removed Dentin Volume, Percentage of Uninstrumented Canal Area, and Average Canal Transportation in the Coronal, Middle, and Apical Portions of Canals (mean ± standard deviation) by the 3 File Systems

	Mesiobuccal			Mesiolingual			Distal		
	WaveOne	PTN	PTU	WaveOne	PTN	PTU	WaveOne	PTN	PTU
Volume (mm^3)	1.5 ± 0.6	1.5 ± 0.6	1.5 ± 0.5	1.5 ± 0.5	1.4 ± 0.6	1.4 ± 0.7	4.0 ± 1.2	4.0 ± 1.3	4.0 ± 1.2
△ Volume (mm^3)	1.8 ± 1.182	1.7 ± 1.3	1.9 ± 1.4	1.8 ± 1.2	1.7 ± 1.3	1.9 ± 1.1	1.8 ± 1.3	1.8 ± 1.2	1.7 ± 1.3
Surface before preparation (mm^2)	17.7 ± 5.6	16.8 ± 6.2	16.4 ± 7.7	16.2 ± 5.7	15.9 ± 3.5	16.1 ± 6.8	21.3 ± 4.7	21.5 ± 7.4	22.2 ± 6.9
Noninstrumented surface (%)	39.6 ± 14.7	41.5 ± 14.0	41.4 ± 14.1	35.3 ± 18.5	36.9 ± 13.4	38.4 ± 15.8	52.1 ± 12.6	55.3 ± 12.8	56.3 ± 15.6
Coronal third transportation (μm)	108 ± 28	104 ± 20	108 ± 22	107 ± 26	103 ± 27	107 ± 27	64 ± 24	62 ± 19	67 ± 22
Middle third transportation (μm)	50 ± 23	46 ± 20	50 ± 19	47 ± 20	46 ± 19	48 ± 17	32 ± 18	32 ± 15	32 ± 15
Apical third transportation (μm)	90 ± 24[a]	64 ± 36[b]	92 ± 28[a]	86 ± 25[a]	60 ± 22[b]	88 ± 22[a]	75 ± 30	72 ± 39	81 ± 22

PTN, ProTaper Next; PTU, ProTaper Universal.
Different superscript letters indicate statistically significant differences between groups ($P < .05$).

between each instrument for 1 minute. Irrigants were delivered with a 30-G Max-i-Probe needle (Dentsply-Rinn, Elgin, IL) placed 1 mm short of the WL. After instrumentation, the canal was irrigated with 10 mL 5% NaOCl followed by 5 mL 17% EDTA. Each set of instruments was used to prepare 1 molar (3 canals) only. All root canal preparations were completed by an endodontic resident who had been specially trained with these NiTi instruments, whereas the assessment of preparation by the micro-CT scan was performed blindfolded by another examiner.

The time for canal preparation was recorded by instrumentation time, which included only the time for active instrumentation, and the whole preparation time, which included the total active instrumentation as well as the time used for instrument changes within the sequence and irrigation. The number of fractured and permanently deformed instruments during enlargement was also recorded.

Micro-CT Measurements and Evaluations

The teeth were scanned before and after preparation by using a micro-CT system (μCT -50; Scanco Medical, Bassersdorf, Switzerland) with a resolution of 30 μm. The cross-section images were segmented, registered, visualized, and quantified by using image analysis software (VGStudio Max version 2.0.0; Volume Graphics, Heidelberg, Germany). The following parameters were measured: volume of canals preoperatively, volume of dentin removed, and the percentage of uninstrumented canal surface area. Canal gravity centers were calculated for each scanning slice connected along the z-axis with a fitted line. The center of each section was autosegmented using ImageJ 1.41 software (National Institutes of Health, Bethesda, MD) before and after the instrumentation. The cross-sectional images from the apical foramina to the orifice of each tooth were equally divided into the coronal, middle, and apical portions. Average canal transportations were subsequently calculated by comparing the shifts of the centers in micrometers before and after the instrumentation for the apical, middle, and coronal thirds of the canals.

Statistical Analysis

The means and standard deviations were calculated for each group. One-way analysis of variance was used to determine the difference among groups with SPSS 11.0 software (SPSS Inc, Chicago, IL). The Tukey significant difference post hoc test was performed to find any significant differences between groups. A P value <.05 was regarded as significant.

Results

During the preparation of the canals, no instrument fractured. The mean values of the initial canal volumes and surface areas are shown in Table 1. There were no significant differences between instrument types regarding the uninstrumented area. The instrumentation of canals increased their volume and surface area (Table 1). Significantly less transportation was measured after using PTN files rather than PTU and WaveOne files in the apical third of both mesial canals (Fig. 1*A–D* and Table 1) ($P < .05$). However, there was no statistically significant difference on apical transportation in distal canals among PTN, PTU, and WaveOne systems ($P > .05$). The distal canals had a significantly higher proportion of unprepared surfaces compared with the mesial canals ($P < .05$).

Both instrumentation time and the whole preparation time with WaveOne files were significantly shorter than with the other 2 instruments ($P < .05$). Instrumentation time with WaveOne was 1.32 ± 0.22 minutes followed by PTN (2.87 ± 0.55 minutes) and PTU (4.04 ± 1.47 minutes). The whole preparation time for WaveOne, PTN, and PTU was 3.43 ± 0.28 minutes, 11.47 ± 0.62 minutes, and 19.65 ± 1.62 minutes, respectively.

Discussion

Molars are the teeth most frequently involved in root canal treatment within the general dental practice environment (15, 16). Therefore, it is of interest to evaluate the quality of instrumentation of the entire molar root canal system. When 3 root canals (mesiobuccal, mesiolingual, and distal canals) are present in the mandibular first molar, each canal is flat or oval in the cervical and middle thirds of the root but relatively round in the apical third (17). The mesial root canals usually are curved, with the greatest curvature in the mesiobuccal canal. This canal can have a significant curvature in the buccolingual plane that may not be apparent on radiographs. Therefore, curved mesiobuccal canals often have greater canal transportation by instrumentation than most other canals. The current study focused on the preparation of mandibular molars with curved canals and various cross-sections (ie, curved mesiobuccal canals and oval or flat distal canals) by using 2 recently introduced NiTi instruments (PTN and WaveOne systems) and the PTU system. Teeth selected for this study were similar with respect to geometric parameters (canal curvature and initial canal volumes) before instrumentation (Table 1).

The 3 NiTi instrument systems examined had comparable scores for canal transportation in the coronal and middle portion of the canals. Apically, the lowest canal transportation scores were recorded when PTN instruments were used to prepare the mesial canals. It may be partly explained by the smaller apical taper of PTN X2 (size 25/.06) compared with PTU F2 and WaveOne primary files (both tips are size 25/.08). In general, besides the dimension of the instrument, other factors including the metallurgical properties, instrument design, and the way the instruments are used can influence canal transportation during instrumentation (8–10, 18). Flexible thermomechanically treated NiTi instruments are expected to affect the shaping capability of the canal during instrumentation. However, the shaping capability of endodontic instruments depends on a complex interrelationship between different factors.

The WaveOne Primary file has the same tip size and taper as the PTU F2 but a variable cross-section and reverse cutting blades (19). You et al (20) evaluated the shaping ability of reciprocating motion (RM) in comparison with continuous rotation motion (CRM) with the ProTaper F2 in curved root canals using micro-CT scanning. The results showed that changes in curvature, root canal volume, surface area, and structure model index were not affected by the instrumentation technique used. There were no significant differences in the degrees and directions of transportation between the CRM and RM groups (21). It was indicated that the application of RM during instrumentation did not result in increased apical transportation when compared with CRM. In the current study, there was no difference in apical transportation between WaveOne and PTU files. The shaping ability of WaveOne instruments has been evaluated in plastic blocks and extracted teeth (22–24). Our finding is corroborated by a study (22) of curved root canals in extracted teeth in which Reciproc, WaveOne, Mtwo, and ProTaper rotary instruments maintained the original curvature well with no significant differences between the different files. However, Berutti et al (23) found that the WaveOne Primary reciprocating single file maintained the original canal anatomy better, with less modification of the canal curvature than the ProTaper system up to F2 in standardized curved plastic blocks. Possible reasons for these conflicting findings are different methodologies and models.

Centering ability is influenced both by the design of the instrument (size, taper, flexibility, and type of alloy) and the root canal anatomy. Peters and Paque (9) found that canal transportation was more pronounced when shaping narrow curved canals than in wider canals of

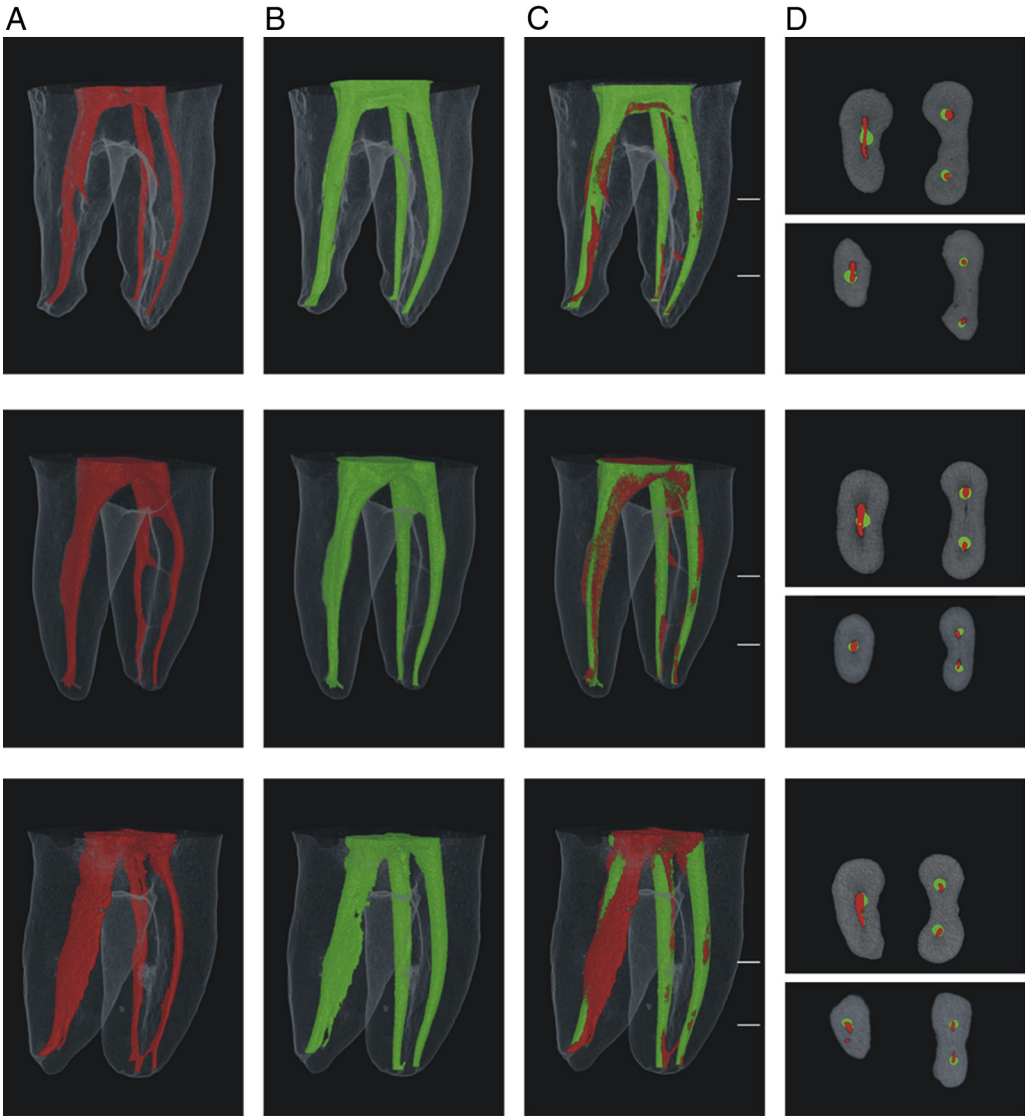

Figure 1. Three-dimensional reconstructed panel of the root canal system of the mandibular first molars representative of the ProTaper Next (top), ProTaper Universal (middle), and WaveOne (bottom) groups. (*A*) Preoperative reconstructions, (*B*) postoperative reconstructions, and (*C*) superimposed reconstructions. (*D*) Cross-sections for the middle and apical portions. The red color indicates the preoperative area, and the green color indicates the postoperative area.

maxillary molars. In agreement with the present findings, curved mesial canals had larger canal transportation than wide straight distal canals (9). In addition, preoperative canal anatomy is likely to play a role when assessing the amount of uninstrumented canal areas after preparation (8). As expected, the current study showed that wide distal canals (52%–56%) had significantly more untouched areas than the narrow mesial canals (35%–41%). It has been proposed that canals should be prepared to sufficiently large apical sizes to optimize irrigation and disinfection and to facilitate the elimination of microbes mechanically (25). With respect to the root canal anatomy in human mandibular molars, the distal canal of each tooth in the current study was prepared to a bigger size than the mesial canals (#40 vs #25). Ideally, an apical size would be determined specifically for each individual canal but that would not permit statistical analysis within the framework of the current experiment.

The WaveOne technique, including irrigation, required significantly less time than preparation with PTN and PTU. Less time used for instrumentation is a potentially attractive feature of the WaveOne single-file technique compared with multiple-files technique (eg, PTN and PTU systems). However, it is important to keep in mind that the short overall time of instrumentation may not have permitted enough contact time for the irrigants to aid in debriding canal irregularities untouched by the file and for killing microbes. Cleaning and removing of necrotic tissue, debris, and biofilms from untouched areas rely completely on chemical means, and sufficient use of sodium hypochlorite is the key factor in obtaining the desired results in these areas (26). It has been suggested that the reciprocating systems may push more debris, bacteria, and irrigants through the apical foramen or into the irregularities of the canal space than conventional instrumentation systems (27, 28). This further emphasizes the importance of efficient root canal irrigation with the single-file approach.

Under the conditions of this study, WaveOne, PTN, and PTU instruments shaped root canals in mandibular first molars *in vitro* without significant shaping errors. Curved canals prepared with PTN had less apical transportation than canals instrumented with WaveOne or PTU files.

Acknowledgments

Supported in part by start-up funds provided by the Faculty of Dentistry, University of British Columbia, Canada, and Canada Foundation for Innovation (CFI fund; Project number 32623).

The authors deny any conflicts of interest related to this study.

References

1. Peters OA. Current Challenges and concepts in the preparation of root canal systems: a review. J Endod 2004;30:559–67.
2. Gutmann JL, Gao Y. Alteration in the inherent metallic and surface properties of nickel-titanium root canal instruments to enhance performance, durability and safety: a focused review. Int Endod J 2012;45:113–28.
3. Shen Y, Zhou HM, Zheng YF, et al. Current challenges and concepts of the thermomechanical treatment of nickel-titanium instruments. J Endod 2013;39:163–72.
4. Ye J, Gao Y. Metallurgical characterization of M-Wire nickel-titanium shape memory alloy used for endodontic rotary instruments during low-cycle fatigue. J Endod 2012;38:105–7.
5. Gao Y, Gutmann JL, Wilkinson K, et al. Evaluation of the impact of raw materials on the fatigue and mechanical properties of ProFile Vortex rotary instruments. J Endod 2012;38:398–401.
6. Bryant ST, Dummer PMH, Pitoni C, et al. Shaping ability of .04 and .06 taper ProFile rotary nickel-titanium instruments in simulated root canals. Int Endod J 1999;32:155–64.
7. Peters OA, Laib A, Ruegsegger P, Barbakow F. Three-dimensional analysis of root canal geometry by high-resolution computed tomography. J Dent Res 2000;79:1405–9.
8. Peters OA, Peters CI, Schonenberger K, Barbakow F. ProTaper rotary root canal preparation: effects of canal anatomy on final shape analysed by micro CT. Int Endod J 2003;36:86–92.
9. Peters OA, Paque F. Root canal preparation of maxillary molars with the self adjusting file: a micro-computed tomography study. J Endod 2011;37:53–7.
10. Zhao D, Shen Y, Peng B, Haapasalo M. Micro-computed tomography evaluation of the preparation of mesiobuccal root canals in maxillary first molars with Hyflex CM, Twisted Files, and K3 instruments. J Endod 2013;39:385–8.
11. Schneider SW. A comparison of canal preparations in straight and curved root canals. Oral Surg Oral Med Oral Pathol 1971;32:271–5.
12. Berutti E, Paolino DS, Chiandussi G, et al. Root canal anatomy preservation of WaveOne reciprocating files with or without glide path. J Endod 2012;38:101–4.
13. Endal U, Shen Y, Knut A, et al. A high resolutyion computed tomographic study of changes in root canal isthmus area by instrumentation androot filling. J Endod 2011;37:223–7.
14. Available at: http://www.tulsadentalspecialties.com/Libraries/Tab_Content_-_Endo_Access_Shaping/NEXT_Rotary_File_Tip_Card.sflb.ashx. Accessed September 13, 2014.
15. Kirkevang L-L, Horsted-Bindslev P, Ørstavik D, Wenzel A. A comparison of the quality of root canal treatment in two Danish subpopulations examined 1974–75 and 1997–98. Int Endod J 2001;34:607–12.
16. Bjørndal L, Laustsen MH, Reit C. Root canal treatment in Denmark is most often carried out in carious vital molar teeth and retreatments are rare. Int Endod J 2006;39:785–90.
17. Vertucci FJ, Haddix JE. Tooth morphology and access cavity preparation. In: Hargreaves KM, Cohen S, Berman LH, eds. *Cohen's Pathways of the Pulp*, 10th ed. Mosby Elsevier; 2010:136–222.
18. Peters OA, Schonenberger K, Laib A. Effects of four NiTi preparation techniques on root canal geometry assessed by micro computed tomography. Int Endod J 2001;34:221–30.
19. Webber J, Machtou P, Pertot W, et al. The WaveOne single-file reciprocating system. Roots 2011;1:28–33.
20. You SY, Kim HC, Bae KS, et al. Shaping ability of reciprocating motion in curved root canals: a comparative study with micro-computed tomography. J Endod 2011;37:1296–300.
21. Franco V, Fabiani C, Taschieri S, et al. Investigation on the shaping ability of nickel–titanium files when used with a reciprocating motion. J Endod 2011;37:1398–401.
22. Bürklein S, Hinschitza K, Dammaschke T, Schäfer E. Shaping ability and cleaning effectiveness of two single-file systems in severely curved root canals of extracted teeth: Reciproc and WaveOne versus Mtwo and ProTaper. Int Endod J 2012;45:449–61.
23. Berutti E, Chiandussi G, Paolino DS, et al. Canal shaping with WaveOne Primary reciprocating files and ProTaper system: a comparative study. J Endod 2012;38:505–9.
24. Marzouk AM, Ghoneim AG. Computed tomographic evaluation of canal shape instrumented by different kinematics rotary nickel-titanium systems. J Endod 2013;39:906–9.
25. Dalton BC, Ørstavik D, Philips C, et al. Bacterial reduction with nickel-titanium rotary instrumentation. J Endod 1998;24:763–7.
26. Haapasalo M, Shen Y, Qian W, Gao Y. Irrigation in endodontics. Dent Clin North Am 2010;54:291–312.
27. Bürklein S, Schäfer E. Apically extruded debris with reciprocating single-file and full-sequence rotary instrumentation systems. J Endod 2012;38:850–2.
28. Dietrich MA, Kirkpatrick TC, Yaccino JM. *In vitro* canal and isthmus debris removal of the self-adjusting file, K3, and WaveOne files in the mesial root of human mandibular molars. J Endod 2012;38:1140–4.